



Contents lists available at BioMedSciDirect Publications

International Journal of Biological & Medical Research

Journal homepage: www.biomedscidirect.com



Original Article

A study of incidence of Single coronary artery

Patel MP^{a*}, Dixit DP^b, Pandya AM^c, Gohil DV^d, Singel TC^e

^{a*, d, e} Department of Anatomy, M. P. Shah Medical College, Jamnagar, Gujarat, India

^b Department of Anatomy, J.N. Medical College, Belgaum, Karnataka, India

^c Department of Anatomy, P. D. U. Medical College, Rajkot, Gujarat, India

ARTICLE INFO

Keywords:

Single coronary artery

Coronary artery anomalies

Single coronary ostia

ABSTRACT

Knowledge of the normal & variant anatomy and anomalies of coronary circulation is very important as anomalous coronaries may cause potentially dangerous symptoms and even sudden death. Cadaveric study in an unsuspected population gives the incidence of anomalies and evaluation of the value of screening for such anomalies. 210 hearts (115 males & 95 females) obtained from the Dept of Forensic medicine & Dept of Anatomy, Shree M. P. Shah Medical College, Jamnagar, Gujarat, and Dept of Anatomy, P.D.U. Medical College Rajkot, Gujarat, were dissected to determine the incidence of single coronary artery (SCA) by noting the no. & course of coronary arteries, no. and position of coronary ostia and presence of any cardiac anomalies. Of the 210 hearts, 89.52% showed presence of two coronaries, 10% were having more than two coronaries and 0.48% had a Single coronary artery (SCA). Incidence of SCA in unsuspected population in present study is 0.48%. 1 case of SCA showed single coronary ostium in the left aortic sinus, no cases of SCA with coronary ostium in the right or posterior sinus were found. No case of SCA with associated cardiac anomaly was recorded in present study.

© Copyright 2010 BioMedSciDirect Publications IJBMR -ISSN: 0976:6685. All rights reserved.

1. Introduction

Coronary artery diseases are becoming one of the leading causes of morbidity & mortality in developing countries. Recent advances in coronary arteriography provide accurate localization and identification of anatomical variations and pathologies if any. Coronary artery bypass grafting (CABG) and other modern advances in myocardial reperfusion requires a thorough and complete knowledge of the normal anatomy and possible variations and anomalies of coronary arteries.

Single coronary artery (SCA) is an anomaly in which right & left coronary will start as a common trunk from a single aortic coronary ostium without a pulmonary coronary ostium [1]. It was first described in detail by Banchi in 1903 [1]. It is considered as a rare variation, various studies has found its incidence ranging from 0.04% [2, 3] to 1.00% [4]

According to Sharbaugh & White [3], SCA may be associated with other cardiac defects (41%) or may occur as innocuous findings (59%); however, a small group of cases without coupled cardiac anomalies were associated with sudden death or cardiomyopathy in young adulthood or childhood; hence, presence of this anomaly is of prognostic importance.

SCA has been classified in following subtypes [5]. Type 1: A SCA arises from either the right or left coronary sinus and the terminal branches of the artery enter the territory which would be supplied by missing artery Type 2: Single vessel will divides in such a way as to give rise to branches which simulate the arrangement of both arteries.

* Corresponding Author : Dr. A. M. Pandya

Asst. Prof., Anatomy,
P. D. U. Medical College,
Rajkot, (PIN 360001)

Gujarat, India

Cell: 9426239635

Email:ashishmpandya@gmail.com

Type 3: The third type has an atypical distribution and grossly differs from the normal.

Vlodavers et al. [5] has suggested fourth type where both the coronaries are present but ostium of one is atretic. Here artery with atretic ostium fills retrogradely from the patent artery through collaterals

Most cases of single coronary artery have been reported as case reports [2-9]. These reports of single coronary artery have drawn their samples either from angiographic studies performed for the work-up of chest pain evaluation [2, 3, 9] or from an autopsy population of congenital heart disease [4, 7, 8]. Therefore, such studies failed to provide data on the frequency of occurrence in an unsuspected population.

Genetic and geographic variations in the coronaries are a known fact [9]. Garg et al. [9] and Harikrishnan et al. [2] have reported the incidence of coronary artery anomalies in angiographic studies of the Indian population, while Joshi et al. [10] have reported normal and variant anatomy of the coronary ostia in adult cadavers of Indian origin. The present study was carried out to find the incidence of single coronary artery.

2. Material and Methods

The study material consisted of 210 adult human hearts from cadavers without any knowledge of their socioeconomic status, education, religion or pathology. 58 were fresh hearts (31 males & 27 females), obtained from Dept of Forensic medicine, Shree M. P. Shah Medical College, Jamnagar, Gujarat. While 152 were embalmed hearts obtained from Dept. of Anatomy, Shree M. P. Shah Medical College, Jamnagar, Gujarat (137 hearts, 73 males & 64 females) and from Dept of Anatomy P.D.U. Medical College Rajkot, Gujarat (15 hearts, 11 males & 4 females).

The collected specimens were subjected to dissection. The aortic root was opened and the number and origin of the coronaries were observed. The number & position of aortic coronary ostia, presence of pulmonary coronary ostia (if any) and relevant details about course of coronary arteries were noted. Hearts were also inspected for the presence of any other cardiac anomalies. After the study, the hearts were returned back to the respective Forensic and Anatomy departments.

Data was arranged in the tabular form and appropriate statistical methods were employed to find the incidence of SCA in the study sample.

3. Results

As shown in the table 1, out of the 210 hearts studied 188 (89.52%) showed presence of 2 coronary arteries, 21 (10%) samples had one or more accessory coronary artery (total coronaries >2) and one coronary artery (SCA) was present in 1 case (0.48%). No case of SCA with associated cardiac anomalies was noted.

Table 1: Case distribution of no. of coronary arteries

No. of Coronary arteries	1 (SCA)	2	>2 (Acc. Coronary artery)
No. of Cases (210)	1 (0.48%)	188 (89.52%)	21 (10%)

In the present study, 1 case of SCA showed presence of single coronary ostium in left coronary sinus while no cases of SCA with coronary ostia located in right coronary sinus or posterior sinus were recorded (Table 2).

Table 2: position of coronary ostium in cases of SCA

Ostium	Aortic sinus		
	Right	Left	Posterior
No. of cases	0	1	0

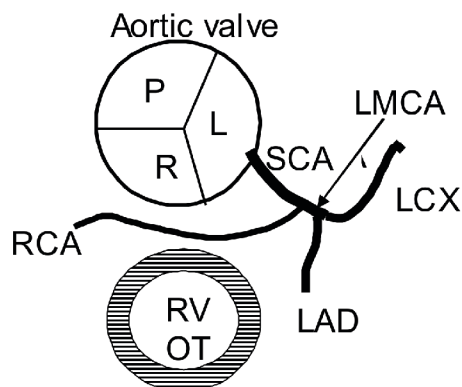
Table 3: Comparison of incidence of SCA in various studies

Name of worker	Incidence
Harikrishna et al.	0.04%
Sharbaugh & White	0.04%
Mishra M. et al.	1.0%
Present study	0.48%

Photo 1: Showing SCA (Single coronary artery) originating from left coronary sinus and dividing in to right coronary (RCA) & left main coronary artery (LMCA)

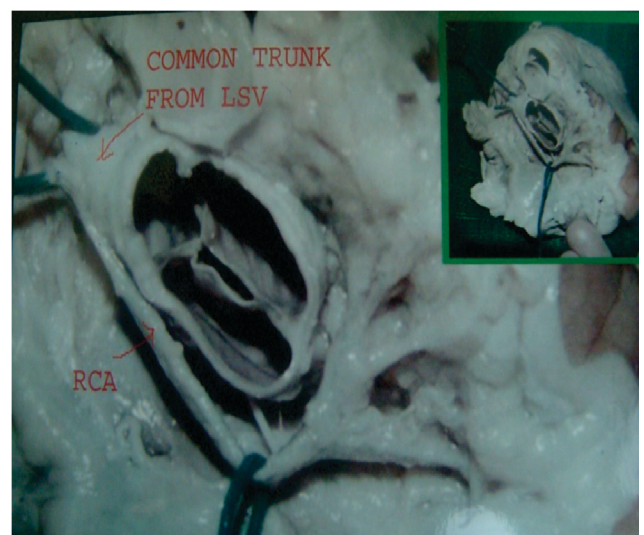

Figure 1: SCA (Single coronary artery) originating from left coronary sinus and dividing into right coronary (RCA) & left main coronary artery (LMCA), (RVOT=right ventricular outflow tract, LAD= let. Ant. Descending, LCX= lt. circumflex)



4. Discussion

The origins of the coronary arteries show great variability, about 90% of anomalies of coronaries were anomalies of origin [9]. Of the 210 hearts studied for the presence of SCA, 1 specimen showed SCA making incidence of SCA 0.48% in present study. 1 case of SCA with coronary ostium in the left sinus was noted, no case of SCA with coronary ostium in either right or posterior sinus were found in the present study

Table 3 showed comparison of incidence of SCA in various studies. Incidence found in present study (0.48%) is nearer to that of the Harikrishna et al [2] and Sharbaugh & White [3]; while findings of the Mishra M. et al [4] were higher than the present result. 41% cases of SCA are associated with other cardiac defects [3]. However, in the present study no case of SCA associated with cardiac anomalies was recorded.

In present study, SCA after its origin from left sinus branched quickly into RCA & LMCA (Type 2). This type of variation with no cardiac anomalies was considered of little clinical significance but sudden cardiac death and myocardial ischemia are reported in this condition giving it prognostic importance [11]. Ischemia in this condition may be due to external compression of coronary by dilated great vessels more so in aged individuals with thickening of vessels [11].

Progenitor tissue delivering stem cells for cardiac development is the proepicardium, which is a transient organ occurring near the venous pole of the embryonic heart, the proepicardium is a source of the epicardial epithelium delivering cellular components of vascular wall; coronary vessel formation proceeds by vasculogenesis and angiogenesis, the first tubules are formed from blood islands which subsequently coalesce forming the primitive vascular plexus and ultimately coronary arteries are formed by directional growth of vascular protrusions towards the aorta and establishing contact with the aortic wall [12]. Any aberration of cell migration or cell signaling during coronary vasculogenesis might be the cause of coronary anomalies like SCA.

During embryogenesis, the coronary arteries originate from those sinuses of Valsalva where wall tension is increased by a catenoidal configuration and the connection of the proximal coronary arteries to the aorta does not appear until Carnegie stage 18 [13]. Any irregularities in wall tension in sinuses of Valsalva may predispose to deviation in normal number & position of coronary ostia

5. Conclusion

Present study found the 0.48% (1 out of 210) incidence of SCA in unsuspected population. 1 case of SCA showed single coronary ostium in the left aortic sinus, no cases of SCA with coronary ostium in the right or posterior sinus were found. 1 case of SCA type 2 was noted, no cases of SCA of type 1, 3, 4 or SCA with associated cardiac anomaly were recorded.

Acknowledgements

Authors are sincerely acknowledging the assistance provided by Dr. B D Gupta Dean, Medical Faculty, Saurashtra University Rajkot, Prof. & Head Dept of Forensic Medicine, M. P. Shah Medical College, Jamnagar Gujarat & we are also thankful to Dept. of Anatomy, P.D. U. Medical College, Rajkot, Gujarat for their kind help

6. References

- [1] Roberts W C, Bathseda M D. Major anomalies of coronary arterial origin seen in adulthood. *Ame. Heart J.* 1986; 111: 941-960.
- [2] Harikrishna S, Jacob S P, Tharakam J M, Titus T, Ajithkumar V K, Bhat A et al. Congenital coronary anomalies of origin and distribution in adults; A coronary angiographic study. *Ind. Heart J.* 2002; 54: 271-275.
- [3] Sharbaugh AH, White RS. Single coronary artery analysis of anatomic variation, clinical importance and report of five cases. *JAMA.* 1974; 230(2): 243-246.
- [4] Mishra M, Puri V K, Masan M. Single coronary artery as an isolated anomaly. *Ind. Heart J.* 1985; 6: 402-404.
- [5] Smith J. Review of single coronary artery with report of two cases. *Circulation* 1950; 1: 1168.
- [6] Vlodavets Z, Amplatz K, Bruchell HB, Edwards JE. Single coronary artery In *Clinical, Angiographic and Pathologic profiles of coronary heart diseases.* Pringer velrlarg; 1976, p. 190.
- [7] Hillestad L, Eie H. Single coronary artery. *Acta Medica Scandinavia.* 1971; 189: 409-412.
- [8] Marvin L. Murphy M. D. Case report- Single coronary artery. *Ame. Heart J.* 1976; 74(4): 557-561.
- [9] Garg N, Tiwari A. Primary congenital anomalies of the coronary arteries: a coronary arteriographic study. *Int J Cardiol.* 2000; 74: 39-46.
- [10] Joshi S D, Joshi S S, Athwale S A. Origins of the coronary arteries and their significance *CLINICS.* 2010; 65(1): 79-84.
- [11] Steven R, Lopushinsky, Mullen J C, Bentley M J. Anomalous Right Coronary Artery Originating From the Left Main Coronary Artery. *Ann Thorac Surg.* 2001; 71: 357-358.
- [12] Ratajska A, Elzbieta C. Bogdan C. Embryonic development of the proepicardium and coronary vessels. *Int J Dev Biol.* 2008; 52: 229-236.
- [13] Hutchins GM, Kessler-H. A, Moore GW. Development of the coronary arteries in the embryonic human heart. *Circulation.* 1988; 77(6): 1250-1257.