



Contents lists available at BioMedSciDirect Publications

International Journal of Biological & Medical Research

Journal homepage: www.biomedscidirect.com



Case report

Wells's syndrome: a case report and review of literature.

Dinesh P Asati^a, Neelesh Arya^b, Chandramohan Kudligi^c

^a Assistant Professor, Department of Dermatology, LN Medical College and JKHMRC, Bhopal

^b Assistant Professor, Department of Pharmacology, Gandhi Medical College, Bhopal

^c Assistant Professor, Department of Dermatology, KIMS, Hubli

ARTICLE INFO

Keywords:

Wells syndrome
Eosinophilic cellulitis
Dermatosis
Dapsone

ABSTRACT

A 77-years-old female presented to us with one month history of gradually progressive, painful erythematous plaque on left periorbital region. In view of clinical and histological features, a diagnosis of Wells' syndrome was established. Since the patient was an elderly female, dapsone was preferred to systemic steroids for treatment. Significant improvement was noted after one month of treatment with dapsone 100 mg once daily and the plaque completely cleared in 12 weeks duration, without leaving any residual atrophy or scarring. Dapsone was stopped and there was no recurrence seen at 3 months follow-up. Conclusion: Wells syndrome or eosinophilic cellulitis is a very rare dermatosis and it can present with wide variety of clinical presentations and differential diagnoses. Awareness of these myriad presentations is needed for its early identification and management to save the patient from undue investigations and treatments. Also, after establishing the diagnosis, search for an underlying inflammatory or proliferative systemic disease should be performed wherever there is some associated clinical or investigation based clue.

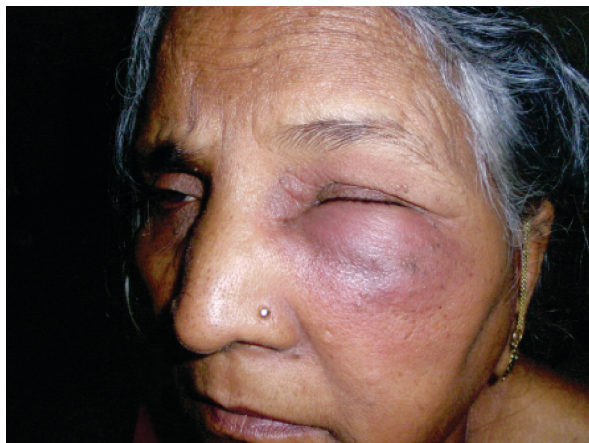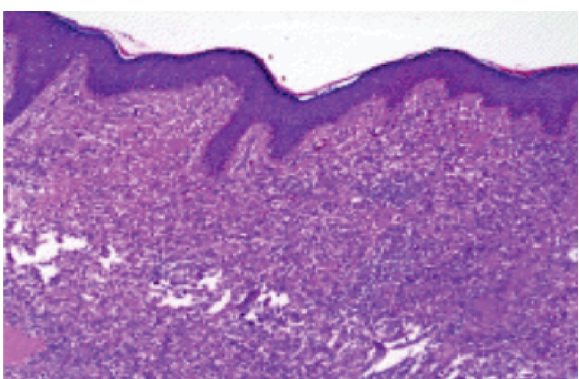
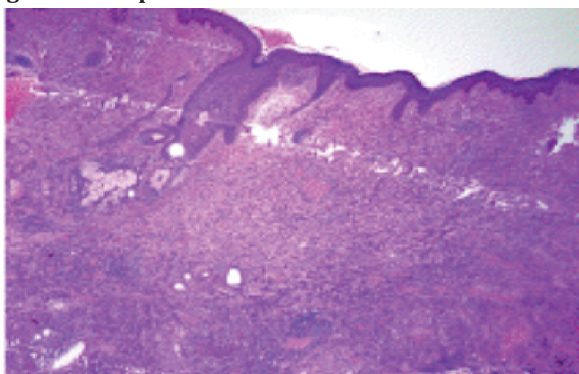
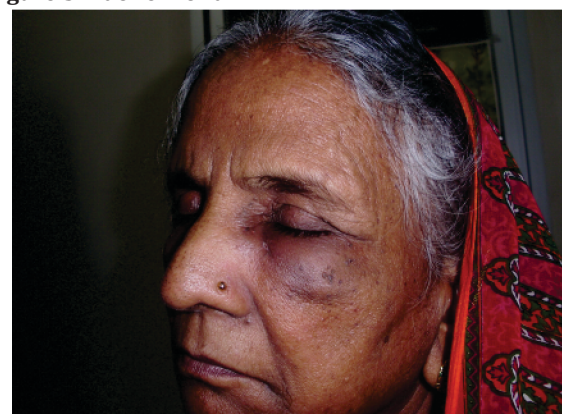© Copyright 2010 BioMedSciDirect Publications IJBMR -ISSN: 0976:6685. All rights reserved.

1. Case report

A 77-years-old female presented to us with one month history of gradually progressive, painful erythematous plaque on left periorbital region. There was no history of any insect bite or trauma prior to the onset of the lesion. Patient had taken various antibiotics before coming to us without any significant improvement. Thorough general physical and systemic examination did not reveal any clues towards any systemic disease. On local examination, an ill-defined, erythematous, mildly tender, non-ulcerated, indurated plaque of size 5cmx5cm was situated on left periorbital region. (Figure 1). Ocular examination revealed, narrowing of the left palpebral aperture due to the edema of both upper and lower eyelids. There was no significant lymphadenopathy. Routine hematologic and biochemical parameters including hemogram, total and differential leucocyte counts, liver and kidney function tests, fasting sugar and urine examination were normal, except mild eosinophilia in peripheral blood (eosinophil count 9 cells/ μ l). Clinical differentials included

cellulitis, deep fungal infection and lympho-proliferative disease. A skin biopsy was done from the plaque, which showed presence of dense superficial and deep diffuse infiltrate of eosinophils and lymphocytes involving the whole of dermis and extending to subcutis. Degranulation of eosinophils was seen in foci with formation of flame figures in the dermis. One such flame figure was surrounded by a palisade of histiocytes. Numerous eosinophils were scattered in the interstitium of the reticular dermis and around the deep vascular plexus. The papillary dermis was edematous (Figure 2). In view of clinical and histological features, a diagnosis of Wells' syndrome was established. Since the patient was an elderly female, dapsone was preferred to systemic steroids for treatment. Significant improvement was noted after one month of treatment with dapsone 100 mg once daily (figure 3) and the plaque completely cleared in 12 weeks duration, without leaving any residual atrophy or scarring. Dapsone was stopped and there was no recurrence seen at 3 months follow-up.

* Corresponding Author : Dr. Dinesh P Asati
Assistant Professor,
Department of Dermatology,
LN Medical College and JKHMRC, Bhopal
E-Mail: dr_chourishi@yahoo.co.in

Figure 1. Pretreatment**Figure 2. HPE photo****Figure 3. At one month.**

2. Review of literature

Wells' syndrome is a distinctive eosinophilic dermatosis of unknown origin. It clinically mimicks acute cellulitis with solid edema and can resolve spontaneously after weeks or months without residues, although recurrences over many years are common [1]. It was first described by Wells in 1971 as a recurrent and autoremissive granulomatous dermatitis with eosinophilia and was later named eosinophilic cellulitis. Since then, about 100 cases of Wells syndrome have been reported in the literature in patients ranging from neonates to the elderly. It has been defined by the following criteria: (i) sudden onset of annular or circinate erythematous-edematous patches that may evolve to morphea-like blue-slate-colored plaques; (ii) a histological picture usually characterized by the presence of 'flame figures'; (iii) non-constant blood hypereosinophilia [2]. Although peripheral eosinophilia may occur, this is not sufficient for diagnosis of the syndrome [3,4]. Etiology and pathogenesis of Wells' syndrome are largely unknown; however, excess production of interleukin-5, the main cytokine responsible for eosinophilic migration in local TH2 responses, has been shown in several cases [5]. Eosinophilic cellulitis may represent a hypersensitivity reaction to circulating antigens or occur as a result of hypereosinophilia in the blood. A variety of triggers like hematologic disorders, arthropod bites, infections like parvovirus B19, photosensitivity, drug administration, or surgery have been mentioned in the literature [6,7]. Many drugs have been causally related to Wells' syndrome, most common being penicillin, tetracycline, anticholinergic agents, anaesthetics, acetyl salicylic acid, adalimumab and infliximab [3-4,8-9].

Clinically it is characterized by an acute dermatitis resembling cellulitis, which evolves into violaceous plaques that resolve spontaneously without scarring. Most frequently affected regions include the trunk, arms, face, and neck. The lesions are often preceded by a prodrome of itching or stinging followed by the development of solitary or multiple, bright red, annular or arcuate plaques or nodules, sometimes with a violaceous border. Recurrences are common. On occasion, residual atrophy and hyperpigmentation may develop as the lesions fade from red to bright pink to slate-gray [5]. Nielsen T et al described atrophic alopecia of the affect scalp as a consequence of eosinophilic cellulitis in an 11 year-old boy [10].

Rarely do patients report systemic symptoms of malaise, fever, or arthralgias [5]. Casazza F et al reported a 40 year old patient with associated fatal myocardial infarction. On autopsy, the aneurysmatic coronary walls were found to be infiltrated by numerous eosinophils, lymphocytes and plasma cells. Similar cellulitis, mainly perivascular, was also noticed in kidneys and anterior mediastinum [11]. Unusual bullous and urticarial presentations have been reported [12]. Eosinophilic annular erythema, a rare figurate dermatitis with a prominent tissue eosinophilia could be a clinical subset of Wells' syndrome. Typical flame figures have been illustrated in few patients with eosinophilic annular erythema [13].

Other inflammatory diseases seen in association with eosinophilic cellulitis include ulcerative colitis, celiac disease and hypereosinophilic syndrome. Ulcerative colitis has been

demonstrated to have a simultaneous onset, concurrent flares and resolution of Wells' syndrome with remission of ulcerative colitis [14]. There are reports of Wells' syndrome in association with celiac disease and concomitant Giardia infestation [15].

Rarely, Wells' syndrome is associated with Kikuchi's disease (benign necrotizing lymphadenitis without neutrophilic infiltration), non-Hodgkin's lymphoma, colon carcinoma, squamous cell carcinoma and adenocarcinoma of lung [12, 16, 17]. Renner R et al exhibited complete disappearance of typical skin findings of Wells' syndrome following chemotherapy and autologous stem cell transplantation for associated angioimmunoblastic lymphadenopathy [18].

Eosinophilic cellulitis should not be confused with hypereosinophilic syndrome (HES), which constitutes a group of idiopathic disorders associated with multiple organ dysfunction, sometimes fatal. The criteria of diagnosis of HES are: persistent idiopathic blood eosinophilia, at least for 6 months; signs or symptoms of organ involvement (haematological, cardiac, pulmonary, rheumatological, gastrointestinal, musculoskeletal, neurological disorders). Cutaneous manifestations are pruritic or erythematous papules, plaques and nodules, with urticaria and angio-oedema, present in more than half of the cases. Histopathological findings are nonspecific with variable dermal infiltration of mixed inflammatory cells, including eosinophils, without evidence of flame figures, because there is insufficient degranulation of eosinophils in the skin. Carlesimo M et al described an interesting patient with borderline hypereosinophilic disease, in which clinical features of both hypereosinophilic syndrome and Wells syndrome were present. The patient showed clinical features of Wells syndrome, along with a diversity of systemic signs and symptoms (parotid glands, pancreas and lungs) [19].

The differential diagnosis includes bacterial cellulitis, arthropod bites, urticarial vasculitis, pressure urticaria, and allergic or irritant contact dermatitis, thrombophlebitis, lipodermatosclerosis, sweet syndrome and deep fungal infections [5, 20-21]. Because of the diverse clinical presentations of Wells' syndrome, many more clinical differentials can appear, so typical histopathology may be quite helpful in confirmation of diagnosis.

The laboratory work-up of patients suspected of having Wells syndrome includes a complete blood cell count, a comprehensive metabolic panel, and a punch skin biopsy. Peripheral eosinophilia is seen in only 50% of cases. If a parasitic disorder is suspected, a stool examination and specific antibody titers are indicated. Histology characteristically reveals a diffuse infiltrate of eosinophils with degranulation, marked edema and the formation of "flame figures" and palisading microgranulomas. Flame figures are formed when degranulating eosinophils coat collagen bundles with eosinophilic major basic protein. However, they can also be seen in other eosinophil-mediated dermatoses, such as eczema, bullous pemphigoid, and arthropod bites [5, 22]. Vasculitis is not seen, and direct immunofluorescence studies are usually negative [5, 22].

Investigators have come across a noteworthy clinico-pathological correlation among a wide polymorphism of the clinical findings and histological features of Wells' syndrome. The clinical features seem to depend on the location of the dermal infiltrate, suggesting the existence of a spectrum of eosinophilic dermatoses, like in neutrophilic dermatoses. The successive occurrence of vasculitis, Wells' syndrome and Sweet's syndrome has been reported in one patient suggesting an overlap between these diseases [23].

The initial treatment of choice for Wells syndrome is oral steroids at doses of 10 to 60 mg daily with slow tapering over several weeks. Recurrences will necessitate retreatment with oral steroids or topical steroids in milder cases. In situations where steroids are contraindicated, other therapy options include dapsone, antihistamines such as cetirizine, oral antibiotics such as minocycline, or antifungals such as griseofulvin [24-25]. Immunosuppressants like azathioprine and cyclosporine have been shown to be effective in several patients. Tacrolimus had been used successfully in cases of steroid-resistant cases of Wells' syndrome [26].

3. Discussion

Some authors have questioned the existence of Wells' syndrome as a separate entity. Schorr WF et al presented evidence of tick or bee bites as a cause of eosinophilic cellulitis like presentation [27]. However, a dilution of Wells' syndrome by making flame figures the central criterion of diagnosis and by lumping all flame figure-positive skin reactions together is invalidated by others [22]. Our patient had quite a classic presentation of eosinophilic cellulitis, although she had only one episode. The patient denied any history of insect bite or other preceding event. Flame figures and eosinophilic infiltration were also present in the skin histopathology. These standard findings really narrowed down the clinical differentials for our patient. She was given systemic antibiotics before presenting to us indicating that her lesion was thought to be bacterial cellulitis previously. Clinically, pyogenic cellulitis is the most common simulator to Wells' syndrome and patient often gets treated by higher antibiotics for a long time before actual diagnosis is thought of [21]. There were no systemic findings or identifiable underlying cause for her skin lesions, and many times it is not possible to find one [1]. Dapsone could be a good alternative to systemic corticosteroids or other immunosuppressive agents as our patient was an elderly female. She responded successfully to this therapy and all the lesions resolved slowly without leaving any scarring or residual pigmentation. However, cases can resolve spontaneously, making it difficult to determine the effectiveness of treatments [5]. The patient did not show recurrence in three month treatment free period, however, further follow-up may be needed to ensure complete remission.

4. Conclusion

Wells' syndrome or eosinophilic cellulitis is a very rare dermatosis and it can present with wide variety of clinical presentations and differential diagnoses. Awareness of these myriad presentations is needed for its early identification and

management to save the patient from undue investigations and treatments. Also, after establishing the diagnosis, search for an underlying inflammatory or proliferative systemic disease should be performed wherever there is some associated clinical or investigation based clue.

5. References

- [1] Holme SA, McHenry P. Nodular presentation of eosinophilic cellulitis (Wells' syndrome). *Clin Exp Dermatol* 2001; 26: 677-9.
- [2] Ferreli C, Pinna AL, Atzori L, Aste N. Eosinophilic cellulitis (Well's syndrome): A new case description. *J Eur Acad Dermatol Venereol* 1999; 13: 41-5.
- [3] French LE, Shapiro M, Junkins-Hopkins JM, Wolfe JT, Rook AH. Eosinophilic fasciitis and eosinophilic cellulitis in a patient with abnormal circulating clonal T cells: Increased production of interleukin 5 and inhibition by interferon alfa. *J Am Acad Dermatol* 2003; 49: 1170-1174.
- [4] Seckin D, Demirhan B. Drugs and Well's syndrome: a possible casual relationship? *Int J Dermatol* 2001; 40: 138-140.
- [5] Maiberger M, Maher I. Pruritic, recurrent, erythematous plaques. *J Am Acad Dermatol* 2011; 64: 214-216.
- [6] Toulon A, Bourdon-Lanoy E, Hamel D, Fraitag S, Leruez-Ville M, de Prost Y, Hadj-Rabia S. Wells' syndrome after primo-infection by parvovirus B19 in a child. *J Am Acad Dermatol* 2007; 56: S51-52.
- [7] Kwah YC. Photosensitivity: a possible cause for Wells' syndrome? *Photodermatol Photoimmunol Photomed* 2008; 24: 52-54.
- [8] Boura P, Sarantopoulos A, Lefaki I, Skendros P, Papadopoulos P. Eosinophilic cellulitis (Wells' syndrome) as a cutaneous reaction to the administration of adalimumab. *Ann Rheum Dis* 2006; 65: 839-840.
- [9] Tugnet N, Youssef A, Whallett AJ. Wells' syndrome (eosinophilic cellulitis) secondary to infliximab. *Rheumatology (Oxford)*. 2011 Oct 22. [Epub ahead of print]
- [10] Nielsen T, Schmidt H, Søgaard H. Eosinophilic cellulitis. (Well's syndrome) in a child. *Arch Dermatol* 1981; 117: 427-429.
- [11] Casazza F, Fiorista F, Boeri R. Well's syndrome with eosinophilic vasculitis, coronary aneurysms and myocardial infarction. *G Ital Cardiol* 1989; 19: 923-927.
- [12] Spinelli M, Frigerio E, Cozzi A, Garutti C, Garavaglia MC, Altomare G. Bullous Wells' syndrome associated with non-Hodgkin's lymphocytic lymphoma. *Acta Derm venereol* 2008; 88: 530-531.
- [13] Rongioletti F, Fausti V, Kempf W, Rebora A, Parodi A. Eosinophilic annular erythema: an expression of the clinical and pathological polymorphism of Wells syndrome. *J Am Acad Dermatol* 2011; 65: e135-7.
- [14] Wells' syndrome associated with ulcerative colitis: a case report and literature review. *Sakaria SS - J Gastroenterol* - 01-MAR-2007; 42: 250-252.
- [15] Eren M, Açıkalın M. A case report of Wells' syndrome in a celiac patient. *Turk J Gastroenterol* 2010; 21: 172-174.
- [16] Viseux V, Schoenlaub P, Marciniak S, Staroz F, Plantin P. Kikuchi's disease associated with cutaneous manifestations evoking Well's syndrome. *Ann Dermatol Venereol*. 2003; 130: 1150-1153.
- [17] Skellett A. Eosinophilic cellulitis caused by adenocarcinoma of the lung. *Int J Dermatol* 2009; 48: 1402-1403.
- [18] Renner R, Kauer F, Treudler R, Niederwieser D, Simon JC. Eosinophilic Cellulitis (Wells' Syndrome) in Association with Angioimmunoblastic Lymphadenopathy. *Acta Derm Venereol* 2007; 87: 525-528.
- [19] M. Carlesimoa, L. Fidanzaa, E. Maria, G. Feliziania, A. Narcisia, G. De Marcoa, A. Bartolazzib, G. Wells Syndrome with Multiorgan Involvement Mimicking Hypereosinophilic Syndrome. *Case Rep Dermatol* 2009; 1: 44-48.
- [20] Moossavi M, Mehregan DR. Wells' syndrome: A clinical and histopathologic review of seven cases. *Int J Dermatol* 2003; 42: 62-7.
- [21] Gandhi AK, Coloe BJ, Peters C, Darabi K. Wells Syndrome (Eosinophilic Cellulitis): A Clinical Imitator of Bacterial Cellulitis. *The journal of clinical and aesthetic dermatology* 2011; 4: 56-57.
- [22] Aberer W, Konrad K, Wolff K. Wells' syndrome is a distinctive disease entity and not a histologic diagnosis. *J Am Acad Dermatol* 1988; 18: 105-14.
- [23] Consigny S, Courville P, Young P, Richard C, Gauthier V, Maillard V, Detienne A, Joly P, Lauret P. Histological and clinical forms of the eosinophilic cellulitis (Wells' syndrome). *Ann Dermatol Venereol* 2001; 128: 213-216.
- [24] Sharma PK, Gautam RK, Sharma AK. Eosinophilic cellulitis - A case study and management with griseofulvin. *Indian J Dermatol Venereol Leprol* 1995; 61: 163-164.
- [25] Wozel VEG. Innovative Use of Dapsone. *Dermatol Clin* 2010; 28: 599-610.
- [26] Ohtsuka T. Oral tacrolimus treatment for refractory eosinophilic cellulitis. *Clin Exp Dermatol* 2009; 34: e597-8.
- [27] Schorr WF, Tauscheck AL, Dickson KB, Melski JW. Eosinophilic cellulitis (Wells' syndrome): histologic and clinical features in arthropod bite reactions. *J Am Acad Dermatol* 1984; 11: 1043-1049.