



Contents lists available at BioMedSciDirect Publications

International Journal of Biological & Medical Research

Journal homepage: www.biomedscidirect.com



Original Article

Histogenesis of nucleus proprius of lumbar spinal cord of fullterm human foetus

Bhimaidevi. N ^a, Narasingarao B ^b, Sunitha V ^c, Pramila Padmini ^d

^a Associate Professor, Department of Anatomy, MIMS.

^b Professor & HOD, Department of Anatomy, MIMS

^c Professor, Department of Anatomy, MIMS.

^d Assistant professor of Anatomy, MIMS.

ARTICLE INFO

Keywords:

Nucleus proprius
Substantia gelatinosa Rolando
Quantitative study
Morphometric study
Population study

ABSTRACT

Dorsal horn of grey matter of spinal cord is key centre for perception of not only nociceptive but also other sensory modalities. Earlier authors designated six laminae for the dorsal horn in different mammals including human. The literature available on the cytoarchitecture of nucleus proprius of human foetal spinal cord is meager. The present study is an attempt to observe histomorphometry of neurons of nucleus proprius of lumbar segment of spinal cord numerical density and population study of nucleus proprius. The spinal cord of a destitute full term foetus has been dissected and processed for light microscopic study. Holm's silver nitrate staining was done for all sections. Nucleus proprius was found to be bulbous. There is a difference between right and left nucleus proprius in as far as morphometry, numerical density and population study of right and left nucleus proprius

© Copyright 2010 BioMedSciDirect Publications IJBMR -ISSN: 0976:6685. All rights reserved.

1. Introduction

Dorsal horn of the spinal cord is the key centre for the perception of not only nociceptive but also other sensory modalities. Substantia gelatinosa of Rolando was first identified to have been associated with nociception by Rolando. Later in 1888 Waldeyer identified a similar group deeper to substantia gelatinosa. Rexed [1] hypothesised a six horizontal laminar pattern arranged dorsoventrally and designated the laminae in roman numerals. Lamina II corresponds to substantia gelatinosa while the nucleus proprius corresponds to lamina III and IV [2]. The literature reveals the availability of tract cell neurons and inter neurons in the nucleus proprius. A full term destitute foetus after perfusion with 10% formalin was subjected to laminectomy. Lumbar segment of the spinal cord has been dissected and processed for study under light microscope. Histomorphometry of nucleus proprius in rat lumbar spinal cord by cresyl fast violet stained preparations were used for recording various measurements by Abercrombie's method [3] by Bharadwaj et al [4]. Two zones have been identified in the nucleus proprius namely dorsal and ventral by the above authors. The authors observed dominance of spindle cells in dorsal as well as ventral divisions of

nucleus proprius. Round cells were also encountered the fine architecture of dorsal horn and were studied by Ralston H [5] in macaque, in cat spinal cord by Ralston JJ [6], by Leonard, R.B and Cohan, D.H [7] in the spinal cord of pigeon. However the cytoarchitecture of human foetal dorsal horn of spinal cord was not traced in literature, an attempt is made to study the cytoarchitecture of human foetal spinal cord lumbar segment with reference to histomorphometry, numerical density & population study.

2. Materials and methods

One full term destitute male foetus available at the department of anatomy MIMS medical college is the study material. The foetus has been perfused with 10% formalin as per the protocol. After 72 hours laminectomy was done and the spinal cord was exposed. Lumbar segment was identified and 1mm thick lumbar spinal cord segment was processed for light microscopic study. Five microns thick sections were taken and stained with H and E, and Holue's silver nitrate stain for identification of the tract cells of nucleus proprius. Morphometric studies as well as population studies have been done. The nucleus proprius constituted rounded and spindle shaped neurons. After going through all the sections, the length and breadth of nucleus proprius was calculated by using stage and eye piece micrometer. The volume was calculated by $\frac{4}{3}\pi r^3$ of the physics formula. The formula advocated by Saleem and Krishna Murthy [8] i.e. number of cells per cubic mm X total volume of the nucleus = total number of cells in the nucleus proprius was used.

* Corresponding Author : Dr N.Bhimaidevi,

Assoc professor,
Dept of Anatomy,
MIMS.

E.mail: dr.bhimaidevi@yahoo.com

3.Results

The dorsal horn consisting of tract cells and interneurons arranged in nuclear zones. Substantia gelatinosa of Rolando present at the apex was recognized by densely packed small rounded neurons, ventral to this nucleus proprius was identified as a bulbous expansion having an average length of 662.5 microns on right side and 650 microns on left side, an average breadth of 868.75 microns on right side and 881.25 microns on the left side (fig 1). The nucleus has large and small rounded neurons, not having a restricted area for either of them as the large and small cells are present through out the nucleus alternatively (fig 2). The length and breadth of the neuron is 6.12 microns on right side, whereas 5.575 microns on left side. The diameters of cells differ from right side to left side. The numerical density has been calculated by using the formula $ND = NA / D+T$, where ND is the number of cells per millimetre³, NA is mean number of cells per reticule, D is the mean diameter and T is the thickness of the section [9, 10]. Average of both length and breadth gives mean diameter. Thickness of section was 5 microns. The numerical density of nucleus proprius on right side is 2920750 and on left side 2647063 (table 1). The population study of nucleus proprius revealed 759307 on right side, 694827 on left side (table2).

Fig 1: Showing nucleus proprius Holme's silver nitrate stain 10x10

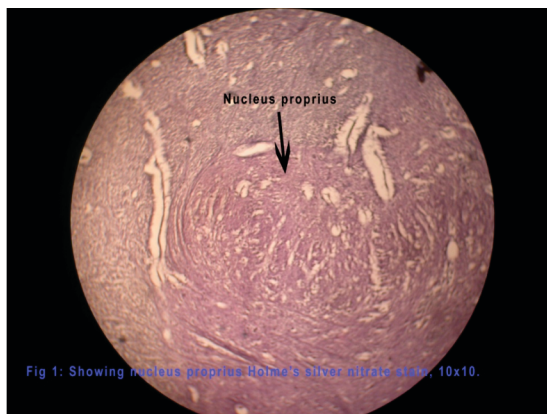


Fig 2: Showing round cells of nucleus proprius Holme's silver nitrate stain 10x40.

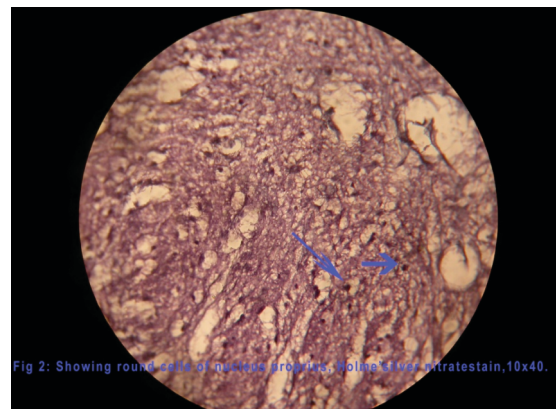


Table 1 showing morphometry of neurons of nucleus proprius

Nucleus proprius	Average length	Average Breadth	Average Volume	Average No of cells per reticule	Numerical density
Right	6.12 microns	6.12 microns	119.19cubic microns	17.875	2920750
Left	5.575 microns	5.575 microns	90.10 cubic microns	14.625	2647063

Table 2 showing population study of nucleus proprius

Nucleus proprius	Average length	Average Breadth	Volume	Population = Numerical Density x volume
Right	662.5 microns	868.75 microns	0.25997 millimeter cube	759307
Left	650 microns	881.25 microns	0.26249 millimeter cube	694827

4.Discussion

Histomorphometry of nucleus proprius has been studied by Bhardwaj et al [4], in rat lumbar dorsal horn of spinal cord. In rat the nucleus proprius could be divided into a dorsal part having smaller neurons and broader ventral part containing loosely dispersed neurons. Rexed [1] and Ralston [5] designated the apex of dorsal horn as substantia gelatinosa and designated it as lamina II. Schizogonthai, J [11] and Scheibel, M.E & Scheibel, A.B [12] could not differentiate lamina II & lamina III in rats and consolidated the 2 zones. The neurons of dorsal division are small and densely packed. Spindle cells also dominated lamina II. Rounded cells constituted the second cell type having 23.18% of total cell population. In the ventral part of nucleus proprius, spindle cells dominated constituting 57.15% of total population, whereas rounded cells contributed 42.5%. Beal, J.A & Cooper, M.H [13] and Ralston, H.J [5] revealed similar finding in the monkey spinal cord. In the present study nucleus proprius of full term of human foetal spinal cord, we

could not observe a clear division of dorsal and ventral parts and nucleus is dominated by rounded cells of various dimensions as mentioned in table 1. There is a difference in cell dimension of nucleus proprius of right and left sides. Similarly nuclear density and population of cells differ from right to left.

On the right side the numerical density is 2920750, whereas on the left side the numerical density is 2647063. The population study revealed a difference between right & left side as shown in table2. The present work revealed that the observations recorded as far as cell dimension, numerical density & population study are of significant value when compared with findings of other workers in mammals. Nucleus proprius is well defined and confined to III, IV, V laminae of grey matter of dorsal horn. No similar study has been made earlier as far as the search of the available literature reveals.

5. References

- [1] Rexed, B. the cytoarchitectonic organization of the spinal cord of cat. Journal of comparative neurology. 1997; 96 : 415-495
- [2] Edited by Peter Williams Gray's Anatomy- 38th edition, p984
- [3] Abercrombie, M. Estimation of nuclear population from microtome sections. Anatomical Record. 1946; 94 : pp239-247.
- [4] Bharadwaj, R, Nagar, M and Prakash, R. Histomorphometry of nucleus proprius in rat lumbar dorsal spinal horn. J. Anat. Soc. India. 2001; 50(2) 140-144.
- [5] Ralston, H. J. III. The fine structure of laminae I, II and III of Macaque spinal cord. Journal of Comparative Neurology. 1979; 184 : 619-642.
- [6] Ralston, J. J. The fine architecture of lamina IV, V, VI of the macaque spinal cord. Journal of comparative neurology. 1982; 212 : 125-134
- [7] Leonard, R. B. and Cohan, D. H. A cytoarchitectonic analysis of the spinal cord of the penguin (Colombia livia). Journal of Comparative Neurology. 1975; 184 : pp 619-642.
- [8] Saleem, K. S. and Krishnamurthy, A. Quantitative study of trochlear nerve nucleus in some primates. Journal of anatomical society of India .1988 : 37(3) 117-124
- [9] Weibel E. R. stereological methods vol 1. in practical methods for biological morphometry. Academic press newyork. 1979.
- [10] Sheriff G. A cell counts in primate cerebral cortex. Journal of comparative neurology. 1953; 98 : 381-400.
- [11] Schizogonthai, J. Neuronal and synaptic arrangement of substantia gelatinosa Rolando, Journal of comparative neurology. 1964; 122: 219-238.
- [12] Scheibel, M. E. and Scheibel, A. B.: The terminal fields of dorsal root fibers in the lumbosacral spinal cord of the cat and the dendritic organization of the motor nuclei. In: Organization of the spinal cord : J. C. Eccles and J. P. Schade (eds) Progress in Brain Research. Vol II. Newyork : Elsevier. 1964; 120-152.
- [13] Beal, J. A. and Cooper, M. H. The neurons in the gelatinous complex (laminae II and III) of the monkey (Macaca mulatta) a Golgi study. Journal of comparative Neurology. 1978; 179: 89-122.